



PATIENT

Wanda Tenorio

SPECIES

Canine

BREED

English Bulldog

SEX

Female Spayed

AGE

11 years

WEIGHT

33.8lbs

INTERPRETED BY

Maggie Machen Lamy,
DVM, DACVIM
(Cardiology)

IMAGING PERFORMED BY

T. Tenorio, DVM

HOSPITAL NAME

Wauwatosa
Veterinary Clinic

REFERRING VET

Dr. Tenorio

INVOICE

21648

DATE

10/21/21

PRESENTING CLINICAL SIGNS

History: Healthy dog, elevated BNP revealed on routine blood screening. No murmur ausculted. Blood pressure average: 145mmHg.

-Abnormal PE/Chem/CBC/UA Results: BNP: 1720 (0-900) CBC/Chem normal otherwise.

ECHOCARDIOGRAM FINDINGS

2D, m-mode, color flow and doppler imaging is available. Mild diffuse thickening of mitral valve leaflets with no prolapse into the left atrial lumen. No mitral regurgitation with no left atrial dilation. Normal LV diameter with adequate myocardial function. The tricuspid valve appears normal with no tricuspid regurgitation. Normal right atrial and ventricular diameter and morphology indicating no overt evidence of pulmonary arterial hypertension. The pulmonic and aortic valves are normal in morphology and mobility. Normal pulmonic and aortic outflow velocities with laminar flow. Mild aortic and trace pulmonic insufficiency. No pericardial or pleural effusion noted. No obvious cardiac masses.

CARDIAC CHART

CANINE CARDIAC PARAMETERS	MR VMAX (m/s)	TR VMAX (m/s)	LA/AO (Boon method)	LA/AO (Heart Base; Swe)	FS (%)	EF (%)	EPSS (cm)
NORMAL PARAMETER	4.5-5.5	<2.7	1.3	<1.6	28-40	40-100	<0.6
PATIENT	NA	NA	1.5	1.3	47	90	NM
CANINE CARDIAC PARAMETERS	HR (BPM)	AV VMAX (m/s)	PV MAX (m/s)	BODY WEIGHT (kg)	LA 2D short axis Base view (cm)	LVIDd Avg; 2D and m-mode short axis (cm)	LVIDs Avg; 2D and m-mode short axis (cm)
NORMAL PARAMETER	50-100	0.7-1.7	0.7-1.6	BELOW	BELOW	BELOW	BELOW
PATIENT	NM	1.8	1.0	15.3	2.3	3.4	1.8
*Normal chamber parameters expressed as a mean value (SD)				3	1.27 (5.3)	2.46 (2.46)	1.36 (5.5)
BODY WEIGHT DEPENDENT PARAMETERS				5	1.40 (4.5)	2.74 (5.2)	1.60 (4.7)
<i>*Note: All measurements based upon multi-modal images and methods. An average value is reported.</i>				10	1.50 (3.8)	3.27 (3.5)	2.06 (3.1)
				15	1.83 (2.0)	3.71 (2.4)	2.43 (2.1)
				20	2.02 (1.9)	4.14 (2.2)	2.80 (2.0)
				25	2.18 (2.4)	4.48 (2.9)	3.10 (2.5)
				30	2.33 (3.3)	4.83 (3.9)	3.39 (3.4)
				35	2.48 (4.3)	5.17 (5.0)	3.69 (4.5)
				40	2.62 (5.2)	5.48 (6.1)	3.96 (5.4)
				50	2.88 (7.1)	6.07 (8.3)	4.46 (7.4)

Adapted from June Boon, Veterinary Echocardiography, 1998
Rishniw M and Hollis NE, J Vet Intern Med 2000; 14:429-435
Hansson et al, Vet Rad and Ultrasound 2002
Bonagura et al. Echocardiography: principles of interpretation, Vet Clin North Am 15:1177, 1995

INTERPRETATION OF THE FINDINGS & FURTHER RECOMMENDATIONS

The cardiac structure and function in this patient is overtly normal. A small aortic leak is noted; however, the reported blood pressure is reasonable. No significant valvular regurgitation is noted, and the cardiac dimensions and function are normal. No obvious cardiac or extra-cardiac tumors are visualized, particularly evaluating along the aortic body. It is important to note that small masses are easily missed; however, suspicion is low in this case as visualization was quite good for the breed.



PATIENT

Wanda Tenorio

No obvious reason for NT-ProBNP elevation is seen, most likely making this a false positive result (a known weakness of the test). Other possible causes should be considered, including hypertension or renal disease. If no obvious cause is identified, reassessing this patient in 6-12 months is recommended to ensure early disease was not missed.

SPECIES

Canine

No cardiac medications are indicated at this time. Monitor for development of a cough, labored breathing, exercise intolerance or collapse episodes.

BREED

English Bulldog

No cardiac contraindication for general anesthesia.

SEX

Female Spayed

A recheck is recommended in 6-12 months to ensure no progressive issues are identified, sooner should a murmur or any clinical signs of cardiac compromise be noted at home.

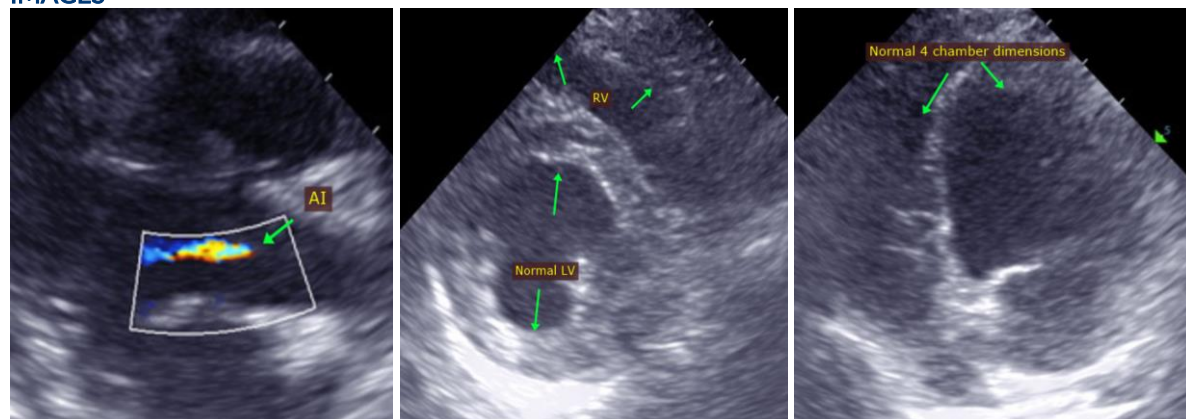
AGE

11 years

IMAGES

WEIGHT

33.8lbs



INTERPRETED BY

Maggie Machen Lamy,
DVM, DACVIM
(Cardiology)

The information and recommendations provided are based on the images presented by the referring veterinarian. No evaluation can be communicated regarding pathology that was not visible in the image/video clips provided.

IMAGING PERFORMED BY

T. Tenorio, DVM

Thank you for this referral. This report was generated using transcription software, and minor dictation errors may be present. If the clinical or image interpretation does not parallel your findings or if I can be of any further assistance, please contact me.

HOSPITAL NAME

Wauwatosa
Veterinary Clinic

Maggie Machen Lamy, DVM
Diplomate of the American College of Veterinary Internal Medicine (Cardiology)
info@sonopath.com

REFERRING VET

Dr. Tenorio

INVOICE

21648

DATE

10/21/21